

## CASE REPORT

# Angioma Serpiginosum in Bilateral Distribution in a Male Child: A Rare Entity with Unusual Presentation

<sup>1</sup>Jasleen Kaur, <sup>2</sup>Karuna Thapar, <sup>3</sup>Simplepreet Kaur, <sup>4</sup>Riya K Kalra

## ABSTRACT

Angioma serpiginosum is a rare benign vascular condition which is characterized by the presence of multiple, minute, erythematous angiomatous macules or patches present in linear blaschkoid, gyrate, or serpiginous patterns. It usually affects lower extremities and buttocks. Involvement of upper trunk and extremities is rare. Histologically, there is dilatation of blood vessels in papillary dermis. Dermoscopic findings reveal presence of oval-to-round red lagoons. It shows female preponderance. Hence, we report a rare case of angioma serpiginosum in a male child with bilateral distribution.

**Keywords:** Angioma serpiginosum, Bilateral distribution, Dermoscopy.

**How to cite this article:** Kaur J, Thapar K, Kaur S, Kalra RK. Angioma Serpiginosum in Bilateral Distribution in a Male Child: A Rare Entity with Unusual Presentation. *Curr Trends Diagn Treat* 2017;1(2):94-95.

**Source of support:** Nil

**Conflict of interest:** None

## INTRODUCTION

Angioma serpiginosum is a rare benign vascular condition where multiple, small, asymptomatic, nonpalpable, deep-red to purple punctate macules are organized in small clusters and sheets. Various patterns have been observed including linear blaschkoid, gyrate, and serpiginous. Peripheral extension with central clearing gives serpiginous appearance.<sup>1</sup> It is usually unilateral in distribution but extensive involvement can also be seen. Commonly involved sites include buttocks and lower extremities. Palms, soles, and mucous membranes are usually not affected.

<sup>1,2</sup>Professor and Head, <sup>3</sup>Junior Resident, <sup>4</sup>Intern

<sup>1,3</sup>Department of Dermatology—Venereology and Leprosy Sri Guru Ram Das Institute of Medical Sciences & Research Amritsar, Punjab, India

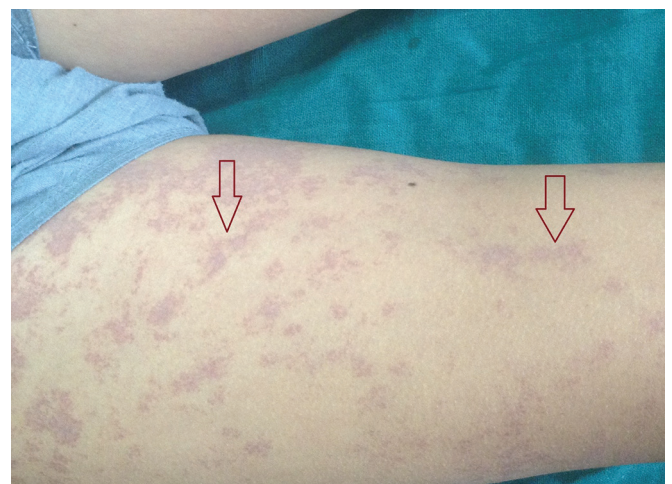
<sup>2</sup>Department of Pediatrics, Sri Guru Ram Das Institute of Medical Sciences & Research, Amritsar, Punjab, India

<sup>4</sup>Department of Internship, Government Medical College Amritsar, Punjab, India

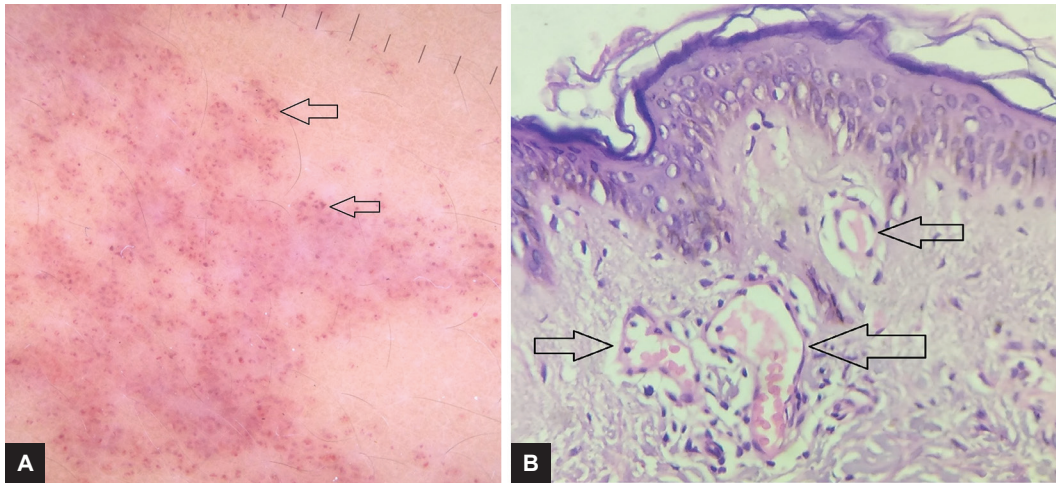
**Corresponding Author:** Simplepreet Kaur, Junior Resident Department of Dermatology—Venereology and Leprosy, Sri Guru Ram Das Institute of Medical Sciences & Research Amritsar, Punjab, India, Phone: +911832870200, e-mail: simple.warraich@gmail.com

## CASE REPORT

A 14-year-old male child presented to the Dermatology outpatient department with the presence of erythematous macules and patches over right thigh and left side of abdomen since birth. For the past 1 month, there was extension of these lesions over right lower limb and left side of back. These lesions were asymptomatic and not associated with pain or itching. On examination, there were multiple, minute, grouped, erythematous macules, and patches present over the affected areas. Serpiginous pattern was also observed over right thigh and leg (Fig. 1). On abdomen, macules coalesced to form an irregular patch. There was no past history of trauma or bleeding from the sites. No other body area was affected. Other systemic examination revealed no abnormality. On diascopy, some lesions were partially blanchable and some non-blanchable. Dermoscopy revealed presence of multiple, minute round-to-oval red lagoons (Fig. 2A). Skin biopsy was performed from affected site for histopathological findings. Histologically, there were dilated blood vessels seen in the superficial dermis (Fig. 2B). There were no epidermal changes or extravasation of red blood cells. All other laboratory investigations, including complete blood count, liver function test, renal function test, viral markers (human immunodeficiency virus, surface antigen of the hepatitis B virus, hepatitis C virus), and urine complete examination, were within the normal limits. Chest X-ray and ultrasound abdomen was also done, which revealed no abnormality.



**Fig. 1:** Multiple minute macules present over the right thigh



**Figs 2A and B:** (A) Dermoscopic picture showing multiple round-to-oval red lagoons (black arrows). (B) Histopathological picture showing dilated blood vessels (black arrows) in superficial dermis (hematoxylin and eosin staining under magnification 400 $\times$ )

## DISCUSSION

In the present case, the following differentials were kept: unilateral nevoid telangiectasia syndrome, port wine stain, pigmented purpuric dermatosis,<sup>2</sup> and incontinentia pigmenti. Based on the history, clinical examination, dermoscopic, and histopathological findings, diagnosis of angioma serpiginosum was confirmed. Angioma serpiginosum begins in childhood and involves females more commonly. Partial and complete regression can be seen. Common sites of involvement include lower extremities and buttocks in unilateral fashion. Along with serpiginous pattern, linear pattern has also been reported.<sup>3</sup> Truncal and acral involvement is usually not seen. In the present case, the affected child was male and truncal involvement was also present along with bilateral distribution of lesions. Estrogen is known to cause proliferation of vascular endothelial cells. Owing to this effect of estrogen, its role has been studied in the development of angioma serpiginosum along with female preponderance.<sup>4</sup> Lately, studies have demonstrated absence of estrogen or progesterone receptors on involved vasculature.

On histopathology, dilated blood vessels can be seen on the background of erythema due to dilatation of subpapillary venous plexus. Periodic-acid Schiff positive deposits can be noticed around involved vessels. No extravasation of red cells can be seen. On dermoscopy, multiple, oval, or round lagoons can be seen.<sup>5</sup> Similar findings were present in our case.

Spontaneous regression may or may not occur. Counseling regarding involution plays an important

role. No topical treatment has been proven efficacious till date. Other treatment modalities include pulse dye laser.<sup>2</sup> Few reports of successful treatment with 532 nm potassium titanyl phosphate laser are present.<sup>6</sup> Our patient was counseled well regarding the treatment options.

## CONCLUSION

Angioma serpiginosum is a chronic condition that may regress partially in some cases. Dermoscopic and histopathological findings help in confirming the diagnosis. This may help patients to avoid unnecessary hematological investigations and undergo undue treatments.

## REFERENCES

1. Namazi MR, Handjani F. Angioma serpiginosum. *Dermatol Online J* 2003 Aug 9(3):19.
2. Ilknur T, Fetil E, Akarsu S, Altiner DD, Ulukus C, Günes AT. Angioma serpiginosum: dermoscopy for diagnosis, pulsed dye laser for treatment. *J Dermatol* 2006 Apr 33(4):252-255.
3. Kalisiak MS, Haber RM. Angioma serpiginosum with linear distribution: case report and review of the literature. *J Cutan Med Surg* 2008 Jul-Aug 12(4):180-183.
4. Xiao X, Hong L, Sheng M. Promoting effect of estrogen on the proliferation of hemangioma vascular endothelial cells in vitro. *J Pediatr Surg* 1999 Nov 34(11):1603-1605.
5. Ghanadan A, Kamyab Hesari K, Moslehi H, Abasi A. Dermoscopy of angioma serpiginosum: a case report. *Int J Dermatol* 2014 Dec 53(12):1505-1507.
6. Rho NK, Kim H, Kim HS. Successful treatment of angioma serpiginosum using a novel 532 nm potassium titanyl phosphate (KTP) laser. *J Dermatol* 2014 Nov 41(11):996-998.